

NEWSLETTER JANUARY

Dear clients,

A new year with new opportunities and hopefully many new adventures! In this newsletter you can read about the Foot and Mouth disease outbreak in South-Africa. Besides, we explain the difference between purring cats and roaring lions! Furthermore, we provide some information about ear notches in rhinos. We hope you enjoy the newsletter! On a general notice, we have upgraded the [Documents-section](#) on our website, it should load a lot faster now.

Best wishes and take care!

Kind regards, Ulf and Mariska

2019

We wish you a prosperous new year, with lots of rain and happiness! Of course we gladly assist you this year again with any veterinary matters, translocations and consultancy. Have a great 2019!



We wish you an amazing 2019!

FOOT AND MOUTH DISEASE

On the 8th of January our Ministry of Agriculture, Water and Forestry suspended the import and transit movement of cloven-hoofed animals and their products from South Africa, due to an outbreak of Foot and Mouth disease. *What is this disease, and what impacts will it have for Namibia?*

What is Foot and mouth disease?

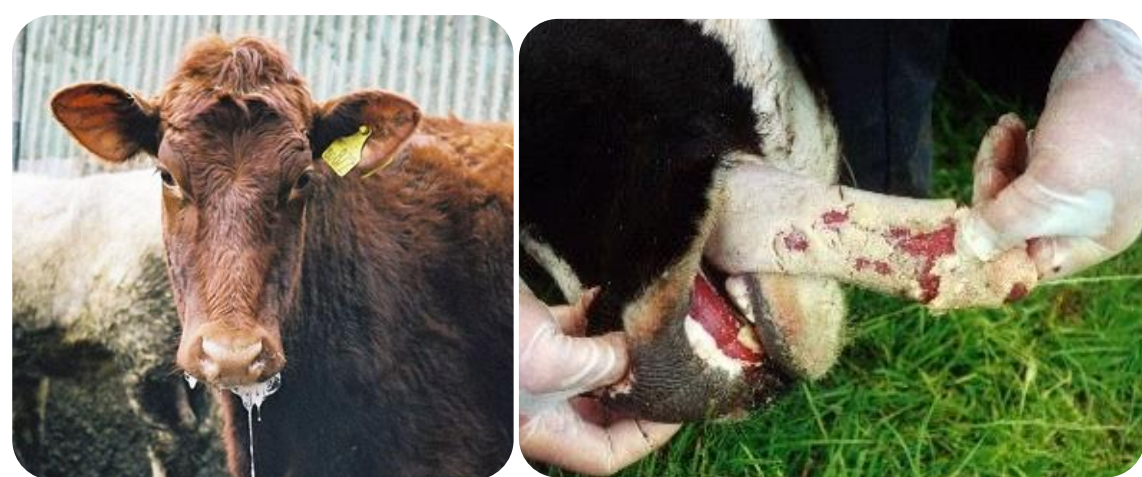Foot and mouth disease (FMD) is a highly contagious viral disease, affecting animals with cloven, or divided, hooves. This includes cows, pigs, sheep, goats, buffalos and antelopes. Elephants can also become infected with the disease. It occurs throughout the world, although some countries have not had the disease for a long time.

The disease is caused by the picornavirus. The virus enters a cell, which then creates thousands of copies of the virus in that cell. The cell eventually bursts, and releases the disease in the body. The disease is transmitted in several ways:

- 🐾 Direct contact (animal to animal contact via mucous membranes, cuts or abrasions)
- 🐾 Indirect contact (e.g. contaminated bedding, water troughs, clothes)
- 🐾 Ingestion (contaminated food)
- 🐾 Respiratory/airborne pathway (inhalation of infectious aerosols)

Animals with FMD have a fever, and vesicles (blisters) on the tongue, lips, in and around the mouth, on the mammary glands and around the hooves. These vesicles pop quickly, causing pain and discomfort, which leads to depression, loss of body condition, excessive salivation, lameness and reluctance to move or stand. Animals rarely die from FMD, but the disease causes appetite suppression, weight loss and reduced milk production which severely weakens the animals. In some cases FMD can lead to myocarditis (inflammation of the heart muscle) and death, especially in new-born animals.

Humans can become infected with FMD, but this is extremely rare. A viral disease with similar symptoms (fever and lesions) which does occur in humans is called 'Hand, foot and mouth disease (FMDV)'. This is however caused by a different virus than the FMD virus.



Photos showing signs of FMD.

Left: cow showing excessive secretion of saliva (drooling) © [LLNL](#).

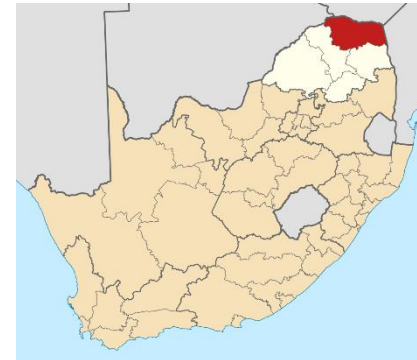Right: deceased cow with blisters on the tongue © [Australian government](#)

FMD occurs all over the world and is highly variable, it continually evolves and mutates. There are 7 known types, and more than 60 subtypes of the virus; immunity for the one type does not protect an animal against infection with the other types. FMD is therefore difficult to control with vaccines.

The outbreak in South-Africa

The 8th of January the news came out that South Africa's Department of Agriculture quarantined an area in Vhembe, in the Limpopo province. After reports came in about lame cattle, samples were collected. Lab results were positive for FMD.

It is estimated that in the 20 km radius of the outbreak about 15 000 cattle are at risk of becoming affected. Livestock will be treated, and a vaccination scheme has started on the 14th, according to the Minister of Agriculture, Forestry and Fisheries Zokwana. The World Organization for Animal Health temporarily suspended the FMD-free status of the country.



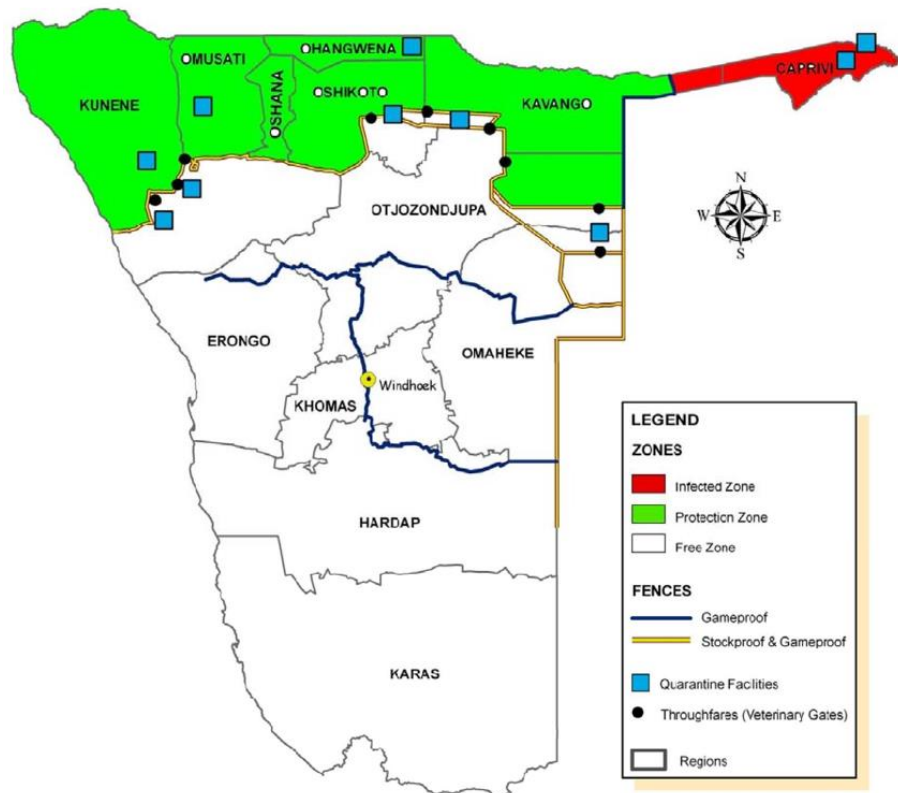
Map of South Africa, showing the Vhembe District Municipality in red © [Htoni](#)

What does this mean for Namibia?

Due to the FMD outbreak in South Africa, Namibia, Botswana, Eswatini (formerly Swaziland) and Zimbabwe banned the import of meat from South Africa for now.

Chairperson of the Namibian Livestock Producers Organisation (LPO), Piet Gouws, said he is optimistic that the domestic red meat demand will be met by local producers. Dairy and pork products might however become scarcer.

When it comes to wildlife, there might be a silver lining for the Namibian game farmers. Since antelopes from South Africa may not be imported, it is likely to increase the price of esp. rare antelope species bred in Namibia. The export of game to South Africa is not affected.



This map shows the FMD zones in Namibia; white: free zone, green; protection zone, red; infected zone. The veterinary cordon fence separates the free zone from the rest. © [van Schaikwyk et al \(2010\)](#)

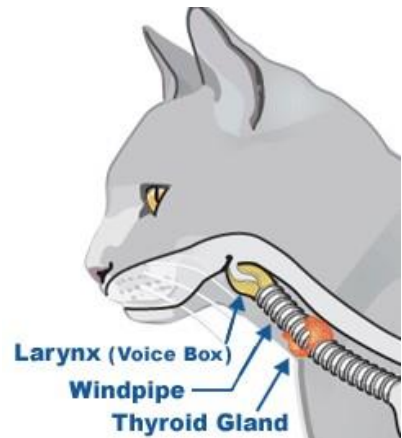
ROARING AND PURRING

When living in Africa, we are quite sure you heard them both... Purring house cats and roaring lions! Although both are cat species, a lion cannot purr, while a cat cannot roar. But why? The secret lies in a small structure which is part of the voice box in the throat; the **hyoid apparatus**.

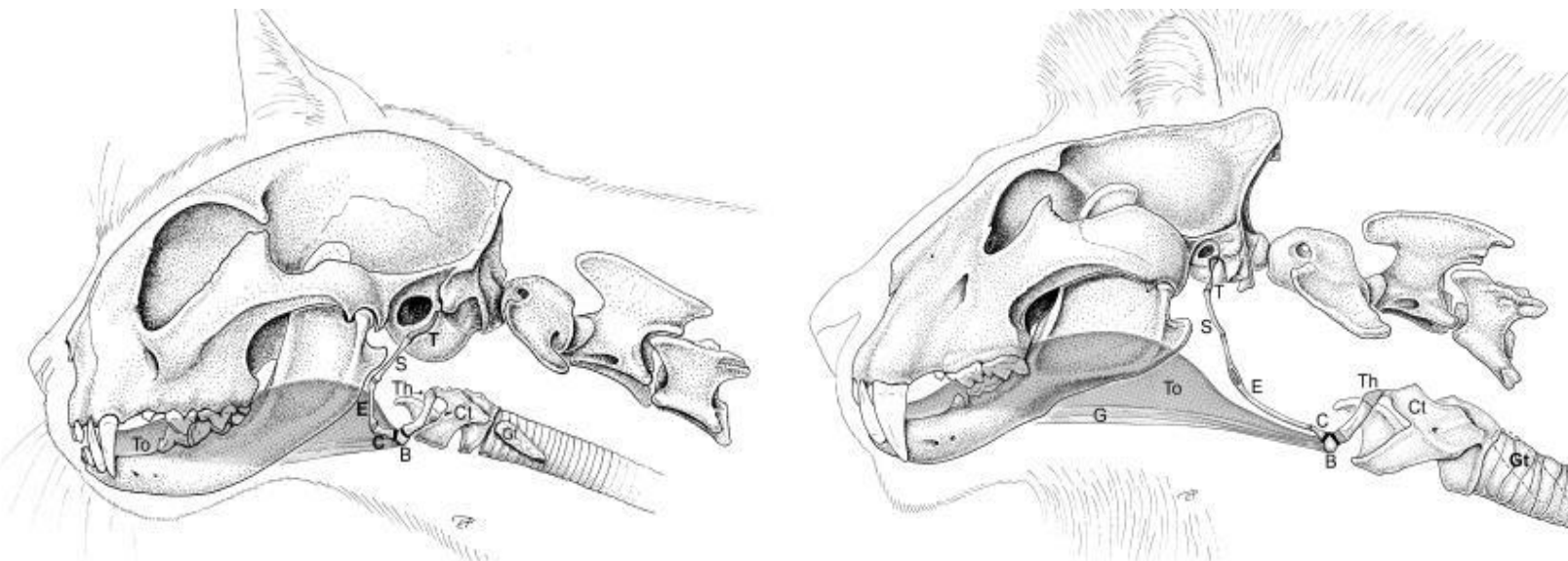
The hyoid apparatus is located in the throat and supports the tongue and larynx (voice box). In small cats (*Felis* genus), the hyoid apparatus is very bony (ossified) and rigid. The bony hyoid and special vocal cords allow air vibrations during in- and exhaling. When a cat purrs, the larynx vibrates, which in turn makes the hyoid bones resonate. In big cats (lions, tigers, jaguars and leopards – all members of the *Panthera* genus) the hyoid apparatus is composed of cartilage instead of bone, and thus a lot softer and flexible. This flexibility, combined with a specialized ligament, helps to produce a deep roaring sound. The more this ligament extends, the lower the sound when air passes through the vocal cords.

The difference in hardness of the hyoid apparatus thus determines whether a cat can purr or roar. They cannot do both. A cheetah and cougar for instance are classified as small cats, based on this anatomical difference.

There is one exception, the snow leopard (member of *Panthera* and thus a big cat) cannot roar. It lacks a fatty elasticated tissue on its vocal cords. Some scientists therefore say the snow leopard needs to be classified in its own genus: *Uncia*.



Position of the larynx in a cat. Picture ©: [IEAS](#)



Anatomical differences between the hyoid apparatus, larynx and cranial part of the trachea between a domestic cat (left) and lion (right).

Abbreviations: T - Tympanohyoideum; S - Stylohyoideum; E - Epihyoideum; C - Ceratohyoideum; B - Basiyoideum; Th - Thyrohyoideum; Cl - Cartilago thyroidea; Gt - Glandula thyroidea. Picture ©: [Weissengrubber et al \(2002\)](#)

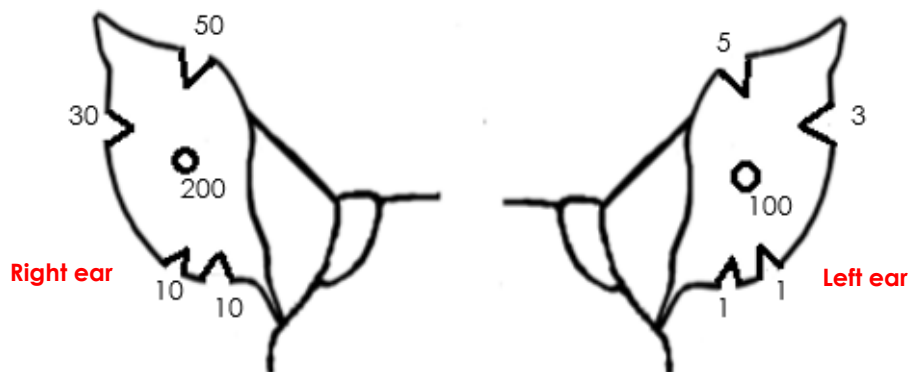
RHINO NOTCHES

To properly monitor your valuable animals, an easy, reliable and “permanent” means of identifying individuals is important. Here we focus on the rhino.

Ear tags, which are often used in cattle, makes identifying individuals easy. However, ear tags are prone to tear out, especially in dense bush. In rhinos ear notches are commonly used, and highly advisable with each rhino getting its own specific pattern of ear notches, with the location of the notches being linked to a numbering system.

Advantages of the notch system are that it permanently identifies individual rhinos and it is generally well-tolerated by tourists. A disadvantage is that there is no universal system, with different countries and conservation organisations, e.g. Zimbabwe, Kruger NP etc. all using their own numbering system. The applied notch system thus may clash with the system of a potential buyer, however, it can easily be adapted into an existing notch system.

In Namibia we usually see the following numbering system:



This 'rhino' is looking towards you. When identifying right and left in animals, we look from the animals' perspective. So imagine yourself being the rhino, and you know what is right and left.

In addition to the visual identification (a **management tool**), we strongly recommend the additional use of microchip implants (a **legal tool as proof of ownership** which can't be modified) to be inserted in the body and both of the horns.



On our website you can view and download a [PDF-document](#) in where you can draw in notches to identify your rhinos in the field.

A as seen from the animal's perspective: this rhino has 2 notches in the right ear; 30 and 10, and 2 notches in the left ear; 3 and 1. Her number is thus 44.

CRAZY JANUARY

We had two rather odd cases this month; a rhino with a tyre around his nose, and a hippo in a swimming pool!



This rhino sure must have felt tired from dragging this tyre around! Luckily he was quickly freed. Rhinos are inquisitive animals, and like sticking their horns in e.g. tyres and roles of wire. Always be aware of rubbish in the veld, and check that e.g. fence teams clean up after their work.

A young hippo bull at Erindi Private Game Reserve was expelled from his group by the older bulls. In his search for 'bluer waters', he ended up in a swimming pool! The hippo was partially immobilized, and released in another area of the reserve.



PRE-RELEASE BOMA ARTICLE ONLINE

In our November newsletter you could read about pre-release bomas. We have converted this into an article, which is free to download from our website. Click [here](#) to open the PDF.

DR ULF TUBBESING
P.O. BOX 50533, BACHBRECHT, WINDHOEK
+264 (0) 81 128 3050
ULFT@AFRICAONLINE.COM.NA
WWW.WILDLIFEVETSNAMIBIA.COM
FACEBOOK: [WILDLIFE VETS NAMIBIA](#)
YOUTUBE: [WILDLIFE VETS NAMIBIA](#)

